



Suspected case of COVID-19-associated Guillain-Barre Syndrome in an Iranian child

Mohsen Mohammadi¹, Yeganeh Baleghi², Sareh Hosseinpour^{3*} 

¹ Assistant Professor of Infectious Disease, Non-Communicable Pediatric Research Center, Babol University of Medical Sciences, Babol, Iran, Dr.mohamadi61@yahoo.com

² MD, Student Research Committee, Babol University of Medical Sciences, Babol, Iran, baleghi.yeganeh@gmail.com

³ Assistant Professor of Pediatric Neurology, Non-Communicable Pediatric Research Center, Babol University of Medical Sciences, Babol, Iran, Hosseinpour.sare@gmail.com

Article Info

Article type:
Case Report

Received:
9 January 2021

Revised:
30 February 2021

Accepted:
28 March 2021

ABSTRACT

Background and Objective: The COVID-19 can cause a broad spectrum of neurologic and systemic manifestations. Case reports on the neurological manifestation of COVID-19 are increasing in the pediatric population.

Case report: In this study, a child suspected to Guillain-Barre Syndrome (GBS) associated with SARS-CoV-19 was reported. This case was a 31-month-old boy presented with transient dysautonomia, progressive symmetric muscle weakness in lower limbs, areflexia with a mild increase in the protein level of cerebro-spinal fluid and no significant evidence of inflammation. The results of an early electromyography-nerve conduction velocities were within normal limit at the fourth day. All radiological and laboratory findings were normal by considering possible causes. Intravenous immunoglobulin was administered, and clinical improvement was remarkable during treatment.

Conclusion: This case report represented an Iranian child with clinically diagnosed GBS, possibly triggered by SARS-CoV-2. It is recommended to consider COVID-19 in children with the neurological presentation in the current outbreak.

Keywords: Pediatric, Covid-19, Guillain-Barre Syndrome, SARS-CoV-2, Nervous system

Cite this article: Mohammadi, et al. Suspected case of COVID-19-associated Guillain-Barre Syndrome in an Iranian child. *Current Research in Medical Sciences*. 2021; 5(1):52-57.



© The Author(s).

Publisher: Babol University of Medical Sciences

***Corresponding Author:** Sareh Hosseinpour, MD, Assistant Professor of Pediatric Neurology. ORCID: 0000-0002-7762-0932

Address: Non-Communicable Pediatric Research Center, Babol University of Medical Sciences, Imam Khomeini avenue, Daroshafa street, Amirkola children hospital, postal code: 4731741151, Babol, Iran.

Tel: +981132353061

E-mail: Hosseinpour.sare@gmail.com

Introduction

In January 2020, the World Health Organization (WHO) reported a new virus as the 2019 novel coronavirus (2019-nCoV) and announced its following disease as coronavirus disease (COVID-19). Regarding to the evidence-based medicine, the CoV can cause a broad spectrum of systemic and neurologic manifestations. While most cases were seen in adult population early in the outbreak, there are now a growing number of cases involving children with COVID-19 1. The most common symptoms were fever and cough, related to the respiratory system 2. A growing number of case reports on the neurological manifestation of COVID-19 which can be para-infectious or post-infectious raise healthcare awareness about symptoms related to CoV 3. Current studies demonstrated the peripheral and central nervous system involvements in SARS-CoV-2 positive patients with the presentation of encephalopathy, ataxia, seizure, stroke and GBS 4-5-6. An Iranian child with dysautonomia and motor weakness, possibly related to COVID-19 infection was admitted in this center.

Case Report

A 31-month-old boy with a history of episodic hypotonia was admitted to the Emergency Department in Amirkola Children's Hospital. He had a normal vaginal delivery, no perinatal insult, negative past medical history, no similar history and no suspicion of COVID-19 in the family, negative recent/remote febrile illness as well as drug history with normal neurodevelopmental status.

A transient attack of hypotonia with preserved awareness in the absence of abnormal movement which occurred one hour before admission was reported as the first manifestation. Two following episodes observed in hospital were described as an episodic hypotonia, fine bilateral rhythmic movements in lower limbs and a doubtful stare for a few seconds without postictal phase. The vital signs monitoring demonstrated hypotension (<70/50 mmHg), tachycardia (heart rate: 114 beats per minute) as well as normal respiratory rate and body temperature during the attack. Glasgow scale, mental status, systemic and neurological examinations were within normal limit at the admission time, and only the irritability was noticeable between attacks in the first day. On the second day of hospitalization, the patient's examination revealed progressive symmetric weakness in the lower limbs, inability to stand, walk even one step and sit, slurred speech, symmetric and bilateral absent deep tendon reflexes (knee and ankle), pain in the lower limbs with normal gag reflex, plantar response and tone, no sign of bowel and bladder dysfunction, cranial nerve palsy, nystagmus, tremor and no clear sensory deficits. In addition, as before, he experienced the fourth and last episodes such as hypotonia and vomiting with detecting hypotension (a sudden fall in systolic blood pressure=60 mmHg) that were longer than previous episodes and without any changes in consciousness and mental status or abnormal movement. No fever or respiratory symptoms were found during admission.

By considering possible causes, all laboratory data, including complete blood count/differential, erythrocyte sedimentation rate, C-reactive protein, serum electrolytes, blood gas analysis, basic metabolic study, creatine phosphokinase level and toxicology screen were within normal limit (Table 1.). Considering the drug toxicity (phenytoin and phenobarbital were used in the management of suspicious seizure in the first day), the antiseizure drug-level monitoring revealed the normal result. The result of two stool samples to identify the polio virus was negative. In regard to the COVID-19 pandemic, the nasopharynx specimen was obtained for Covid-19 polymerase chain reaction (PCR) at day 2, and the test result was positive. The chest X-ray as well as brain and spinal magnetic resonance imaging showed

normal findings (Figure). The electrocardiography, echocardiography and electroencephalography indicated normal results. An early Electromyography-Nerve Conduction Velocities (EMG-NCV) was done on the fourth day, and the results were within normal limit ranges (Supplementary Table1). Unfortunately, his parents refused to do electrophysiology test at the optimum timing after the second week of disease onset. Lumbar puncture was performed on him at day 14, and the cerebro-spinal fluid (CSF) analysis illustrated a mild increase in the protein content (55 mg/dl) with 7 white blood cells (WBCs) and without red blood cell (RBC). The glucose level was normal, and the result of CSF smear and culture was negative. Moreover, the CSF real-time PCR assay for SARS-CoV-2 was negative at the end of second week of the disease onset (Table1). Serology tests for parents were done, and an IgM against SARS-CoV-19 positive result was detected in father.

The child was treated with intravenous phenytoin and phenobarbital for suspected episodes of seizure at an emergency room in the first day. Then, he was clinically suspected to have GBS due to the presence of dysautonomia (fluctuation of blood pressure-hypotension) and progressive weakness, inability to walk, areflexia on the second day, and was admitted to the pediatric intensive care unit. In addition to the cardiac monitoring and supportive care, the intravenous immunoglobulin was administered in doses of 400mg/kg B.w. in 5 consecutive days. Gradually, the autonomic dysfunction disappeared on the first day of IVIG therapy, and clinical improvement in motor weakness was noticeable during course of treatment. He was able to walk with assistance on day 10 of admission, and the normal blood pressure (95/55 mmHg) with weakened deep tendon reflexes was detected during hospitalization. Finally, independent walking and normal deep tendon reflexes were seen at the discharge time and immediate follow-up visits.

Laboratory Test	Result	Unit
WBC ¹	5.1	*10 ³ /qL
Poly	76	%
Lymph	24	%
Hemoglobin	11.8	mg/dL
Platelet	233	*10 ³ /qL
ESR ²	7	mm/h
CRP ³	17	mg/dL
Glucose	131	mg/dL
BUN ⁴	13.5	mg/dL
Cr ⁵	0.6	mg/dL
SGOT ⁶	29	Iu/L
SGPT ⁷	11	Iu/L
Alk ⁸	579	Iu/L
Na ⁹	134	mEq/L
Ca ¹⁰	9.2	mEq/L
K ¹¹	4.0	mEq/L
Mg ¹²	1.9	mg/dL
CPK ¹³	173	u/L
Phenytoin serum level	7.6	mg/mL
Phenobarbital serum level	46	mg/mL
CSF Analysis		
Appearance	Clear	
Glucose	55	mg/dL
Protein	50	mg/dL

WBC ¹⁴	7	/mm ³
RBC ¹⁵	0-1	/mm ³
Poly	20	%
Lymph	80	%

Table 1. Laboratory data of the patient.

1 Complete blood count 2 Erythrocyte Sedimentation Rate 3 C-reactive Protein 4 Blood Urea Nitrogen
 Blood Sodium level 5 Creatinine Blood Potassium level 6 Serum glutamic-oxaloacetic transaminase 7
 Serum glutamic-pyruvic transaminase 8 Alkaline phosphatase 9 Blood Sodium 10 Calcium 11 Blood
 Potassium 12 Magnesium 13 Creatine phosphokinase 14 white cell count 15 Red cell count

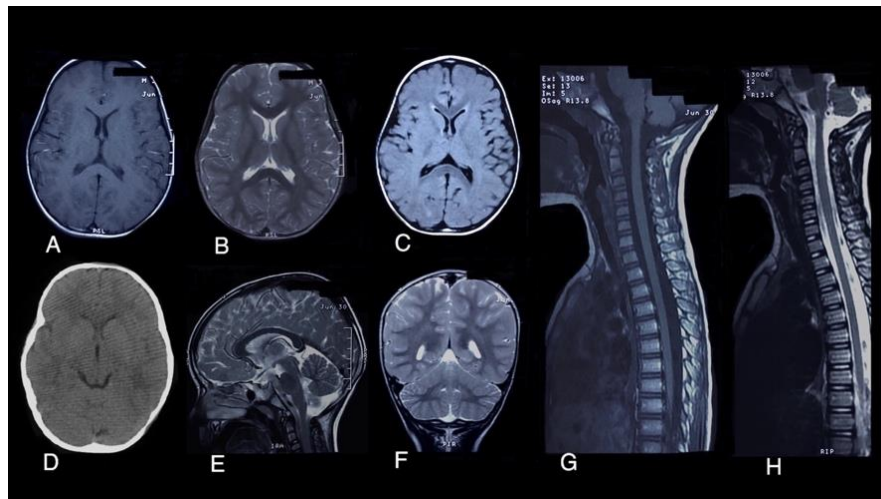


Figure 1. Neuroimaging in the patient showed normal findings. Brain Magnetic resonance imaging (MRI) images (A: Axial T1-Weighted image, B: Axial T2-Weighted image, C: Axial fluid-attenuated inversion recovery, E: Sagittal T2-Weighted image, F: Coronal T2-Weighted image), Brain computerized tomography (CT) scan (D: Axial view), Spine MRI (G, H: Comparison of sagittal T1 vs. T2- Weighted – Spine images)

Discussion

Since the first day of the worldwide outbreak of COVID-19, the number of infected cases with different and new manifestations of coronavirus disease has raised ¹. The SARS-CoV-19 as a member of coronaviridae can cause respiratory, gastrointestinal tract and neurological symptoms in various severities ². Recent reports displayed the importance of the impression of the neurological manifestation due to the CoV ³⁻⁷⁻⁸. This report presented a case of clinically suspected GBS with a positive SARS-CoV-19 test, detected by real-time PCR analysis of nasal swab samples. Our patient had no history of antecedent respiratory, gastrointestinal infections and vaccination. The clinical history of the patient, progressive symmetric muscle weakness in lower limbs, areflexia, transient dysautonomia, absence of fever at the onset of neurologic symptoms, mild increase in the protein level of cerebro-spinal fluid and no significant evidence of inflammation confirmed our diagnosis. Although the early EMG-NCV analysis on the fourth

day of disease onset did not approve this diagnosis, performing this test at the optimal time could be more informative. In parallel to clinical history, further paraclinical evaluations ruled out the differential diagnoses including cerebral, cerebellar, spinal and peripheral nerves disorders, neuromuscular junction and muscle diseases, intoxications (medication, industrial toxin, biologic toxin) as well as poliomyelitis which could be presented with acute weakness. During the hospitalization period, no new pathologic finding was observed in the clinical examination, and the symptoms were improved following the treatment with IVIG. The GBS is an immune mediated acute polyradiculopathy, which is manifested by motor weakness, dysautonomia, sensory symptoms with sign of lower motor neuron involvement on examination. To date, case reports of COVID-19 infected adult patients with GBS have suggested that the peripheral nervous system can be a target for SARS-CoV-19 and develop acute neuropathy as a complication of COVID-19⁷⁻⁸⁻⁹⁻¹⁰. Meanwhile, by continuing pandemic and increasing pediatric population suffering from COVID-19 without typical respiratory or systemic symptoms, the clinicians should consider SARS-CoV-19 in children with new onset neurological manifestation including GBS. Finding a clear relationship between COVID-19 and GBS needs more studies to confirm the role of this virus like other viruses (Coxsackievirus, Adenovirus, Enterovirus, Cytomegalovirus, Epstein-Barr virus, Herpes virus, Influenza, HIV, Zika and so on) as a triggering factor in establishing an immune-mediated processes through various inflammatory phase mediators¹¹⁻¹². It is suggested to evaluate a newly diagnosed GBS patient for COVID-19 infection in the current pandemic, even if there is no significant history of respiratory symptoms or febrile illness.

The limitation of the present case report is the early assessment of neuropathy via EMG-NCV and lack of EMG-NCV data on optimal time due to the parental refusal.

Conclusion

This case report presented an Iranian child with clinically diagnosed GBS, possibly triggered by SARS-CoV-2. It is recommended to consider COVID-19 in pediatric population presented with neurological manifestation in the current active outbreak.

Abbreviation

GBS: Guillain-Barre Syndrome

WHO: World Health Organization

B.W: body weight

CSF: Cerebrospinal fluid

WBC: White blood cell

RBC: Red blood cell

EMG-NCV: Electromyography-Nerve Conduction Velocities

PCR: Polymerase Chain Reaction

IVIG: Intravenous immunoglobulin

Consent for publication

Informed consent was written by parents of our patient to participate in this study.

Acknowledgment

The authors would like to thank the patient and his parents for their cooperation.

ORCID iD

Sareh Hosseinpour <https://orcid.org/0000-0002-7762-0932>

References

1. Xia W, Shao J, Guo Y, Peng X, Li Z, Hu D. Clinical and CT features in pediatric patients with COVID-19 infection: Different points from adults. *Pediatric pulmonology*. 2020 May;55(5):1169-74.
2. Ludvigsson JF. Systematic review of COVID-19 in children shows milder cases and a better prognosis than adults. *Acta Paediatrica*. 2020 Jun;109(6):1088-95.
3. Ellul M, Benjamin L, Singh B, Lant S, Michael B, Kneen R, Defres S, Sejvar J, Solomon T. Neurological Associations of COVID-19. Available at SSRN 3589350. 2020 Apr 24.
4. Abdel-Mannan O, Eyre M, Löbel U, Bamford A, Eltze C, Hameed B, Hemingway C, Hacoheh Y. Neurologic and radiographic findings associated with COVID-19 infection in children. *JAMA neurology*. 2020 Jul 1.
5. Khalifa M, Zakaria F, Ragab Y, Saad A, Bamaga A, Emad Y, Rasker JJ. Guillain-Barre Syndrome Associated with SARS-CoV-2 Detection and a COVID-19 Infection in a Child. *Journal of the Pediatric Infectious Diseases Society*. 2020 Jul 11.
6. Christy A. COVID-19: A Review for the Pediatric Neurologist. *Journal of child neurology*. 2020 Jul 13:0883073820939387.
7. Ahmad I, Rathore FA. Guillain Barr e syndrome in COVID-19: A scoping review. *medRxiv*. 2020 Jan 1.
8. Ahmad I, Rathore FA. Neurological manifestations and complications of COVID-19: A literature review. *Journal of Clinical Neuroscience*. 2020 May 6.
9. Alberti P, Beretta S, Piatti M, Karantzoulis A, Piatti ML, Santoro P, Viganò M, Giovannelli G, Pirro F, Montisano DA, Appollonio I. Guillain-Barré syndrome related to COVID-19 infection. *Neurology-Neuroimmunology Neuroinflammation*. 2020 Jul 1;7(4).
10. Assini A, Benedetti L, Erika S, Del Sette M. New clinical manifestations of COVID-19 related Guillain Barre syndrome highly responsive to intravenous immunoglobulins: two italian cases.
11. Sedaghat Z, Karimi N. Guillain Barre syndrome associated with COVID-19 infection: a case report. *Journal of Clinical Neuroscience*. 2020 Apr 15.
12. Khalifa M, Zakaria F, Ragab Y, Saad A, Bamaga A, Emad Y, Rasker JJ. Guillain-Barre Syndrome Associated with SARS-CoV-2 Detection and a COVID-19 Infection in a Child. *Journal of the Pediatric Infectious Diseases Society*. 2020 Jul 11.