



## A rare case report of multiple stroke in a patient with covid-19 disease

Payam Saadat <sup>1,2\*</sup>, Mohammad Abbasi <sup>3</sup>, Hoda Ebrahimi Ghadikolaei <sup>3</sup>

1. Mobility Impairment Research Center, Health Research Institute, Babol University of Medical Sciences, Babol, Iran.
2. Clinical Research Development Unite of Rouhani Hospital, Babol University of Medical Sciences, Babol,I.R.Iran
3. Student Committee Research, Babol University of Medical Sciences, Babol, Iran

### Article Info

#### Article type:

#### Review Article

#### Received: 1

September 2021

Revised: 20 October  
2021

#### Accepted: 15

December 2021

### ABSTRACT

**Summary:** Human coronavirus (CoV) infection is accompanied by upper and lower respiratory symptoms. It can infect the central nervous system and cause neurological symptoms (including stroke)

Although recent studies have reported the coronavirus's neurological consequences, the neurological manifestations of coronavirus are also ignored.

In this paper, we will discuss the neurological effects of this virus by introducing a stroke after infection by CoV to help diagnose this disease earlier to prevent its side-effects.

**Keywords:** Coronavirus, Stroke, Vascular thrombosis, Neurological

**Cite this article:** Saadat, et al. A rare case report of multiple stroke in a patient with covid-19 disease; *Current Research in Medical Sciences*. 2021; 5(2):48-56.



© The Author(s).

Publisher: Babol University of Medical Sciences

## Introduction

Coronavirus is widely known as a cause of respiratory distress leading to prominent clinical symptoms, including fever and dry cough (2). But it is an undoubted fact that coronavirus can infect the Central Nervous System (CNS). This virus has been found in the nervous system of patients with multiple neurological manifestations, and it is proved that this virus uses axonal transmission (1). Since the outbreak of the coronavirus, most centers have reported that the visit of patients with acute stroke to the emergency department has decreased, and it leads to delay in the treatment of patients, especially in the severe form. Although it does not mean a reduction in the incidence of stroke, it becomes necessary to identify these

\*Corresponding Author: Dr. Payam Saadat

Address: Ganafrouz Street, Babol University of Medical Science, Babol, Iran

Tel: +989111911730

E-mail: sepanta1968@yahoo.com

patients. Therefore, it could be expected that the rate of neurological diseases has an increase in pandemic duration (3).

The Coronavirus can cause deep vein thrombosis (DVT), stroke, and pulmonary embolism and its acute form causes fulminant systemic vascular thrombosis, characterized by rapid, extensive, and progressive peripheral arteriovenous coagulopathy and eventually leads to stroke (4). It can be said that stroke is the main cause of permanent disability in the United States. Approximately 795,000 patients in the United States suffer from a stroke each year, which is currently the fifth cause of death after heart disease, cancer, chronic respiratory disease, and accidents. In fact, 1 in 20 people lost their lives due to stroke (5). Although the chronic risk factors for ischemic stroke are well known, the underlying acute events or stimulating conditions are less known (6).

### **Patient Presentation**

The patient was a 40-year-old married woman, from Babol (north of IRAN), with a previous history of corona disease about a month ago and hospitalized (Figure 1), who presented with a complaint of paresthesia of the left upper and lower limbs and was admitted with an initial diagnosis of stroke. After admission to the emergency room, she was visited by the neurology service and asked an emergency Brain CT for the patient. Initial measures including lab tests, BS Glucometry, ECG were requested. Bilateral hypodense lesions in the hemisphere of the brain and cerebellum were seen in Brain CT (Figure 2), and the patient was admitted to the neurology service for further investigation. Concomitant treatment with enoxaparin anticoagulant was started for the patient at a dose of 60 mg subcutaneously every 12 hours. On the first day of admission, the patient underwent left hemiparesis, and on the second day of admission, she underwent right hemiparesis, and a day later, she suffered impaired consciousness. Doppler ultrasound of the carotid artery was asked for the patient in which evidence of mild atherosclerosis in the form of small intimal plaques was seen. The image of a calcified plaque with the dimensions of  $3 \times 1.5$  mm was seen in the proximal of the right ICA, which did not cause significant stenosis. Infectious service visited the patient. The patient was treated with intravenous dexamethasone 8 mg every eight hours, and PCR Covid 19 was also requested. Additionally, ceftriaxone 2g stat & 1g BD and azithromycin 500mg stat & 250mg BD were started. Cardiac counseling was requested along with echocardiography, which reported normal. Brain MRI was requested for the patient, along with MRA and MRV. In the DWI view, large infarcts were seen in both hemispheres (Figure 3). MRA and MRV were normal. LDH, CPK, IL-6, D-dimer tests were requested, and also during rheumatology consultation, vascular collagen tests including C-ANCA, P-ANCA along with ANA Profile were requested (Table 1). Neurosurgery consultation was requested for the patient, who was advised to perform Brain MRI and Cervical MRA with contrast, and the patient was admitted to ICU. During the hospitalization, the patient suddenly became lethargic and weakened in the right upper and lower extremities. Another Brain CT was asked, and an emergency CBC, PT, PTT, INR test. A hemorrhagic lesion could be seen on CT (Figure 4).

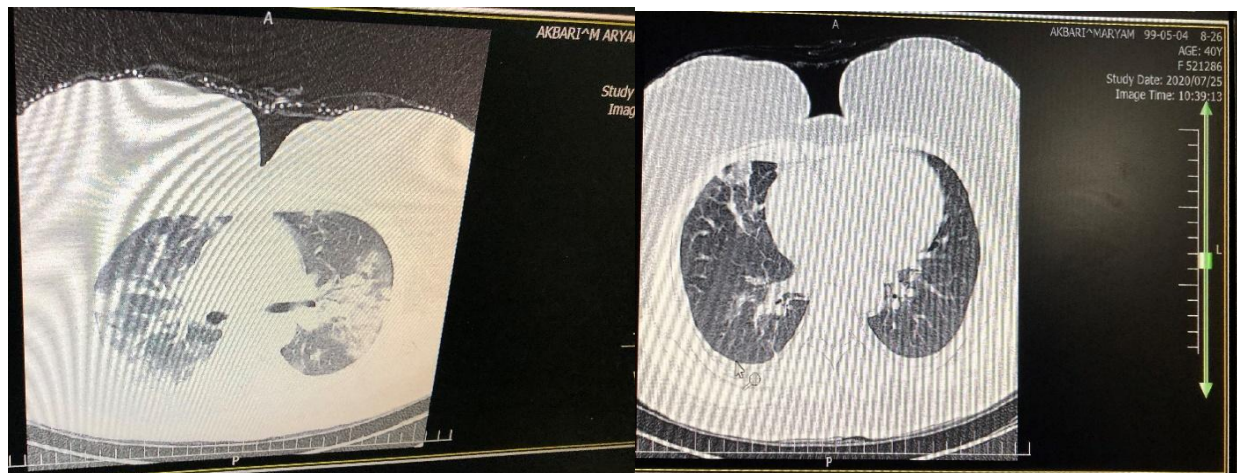


Fig1: Bilateral multilobar ground glass/Consolidation opacities in the lung which is highly suggestive for Covid 19 Pneumonia

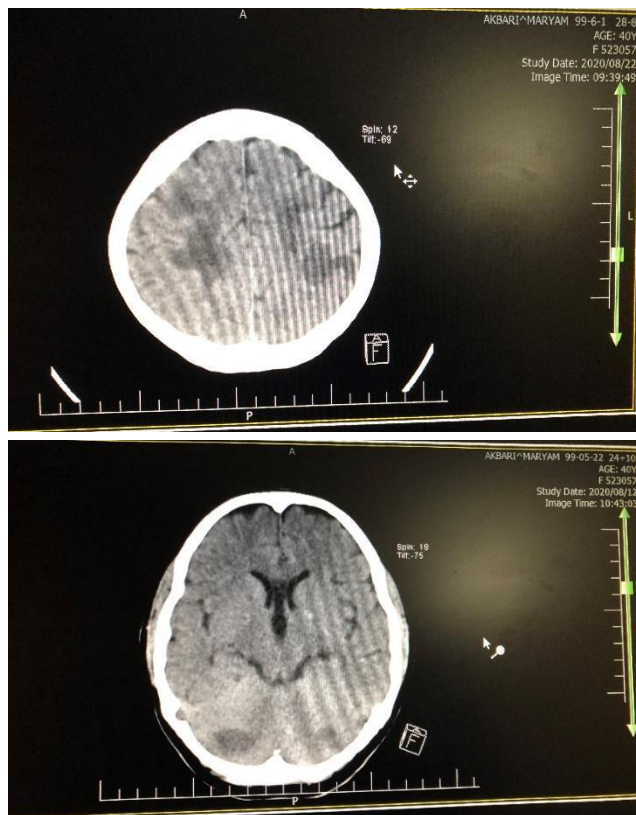


Fig2: Spiral Brain CT scan without contrast.  
Hypodensity in both of the cerebellar hemispheres and high parietal regions

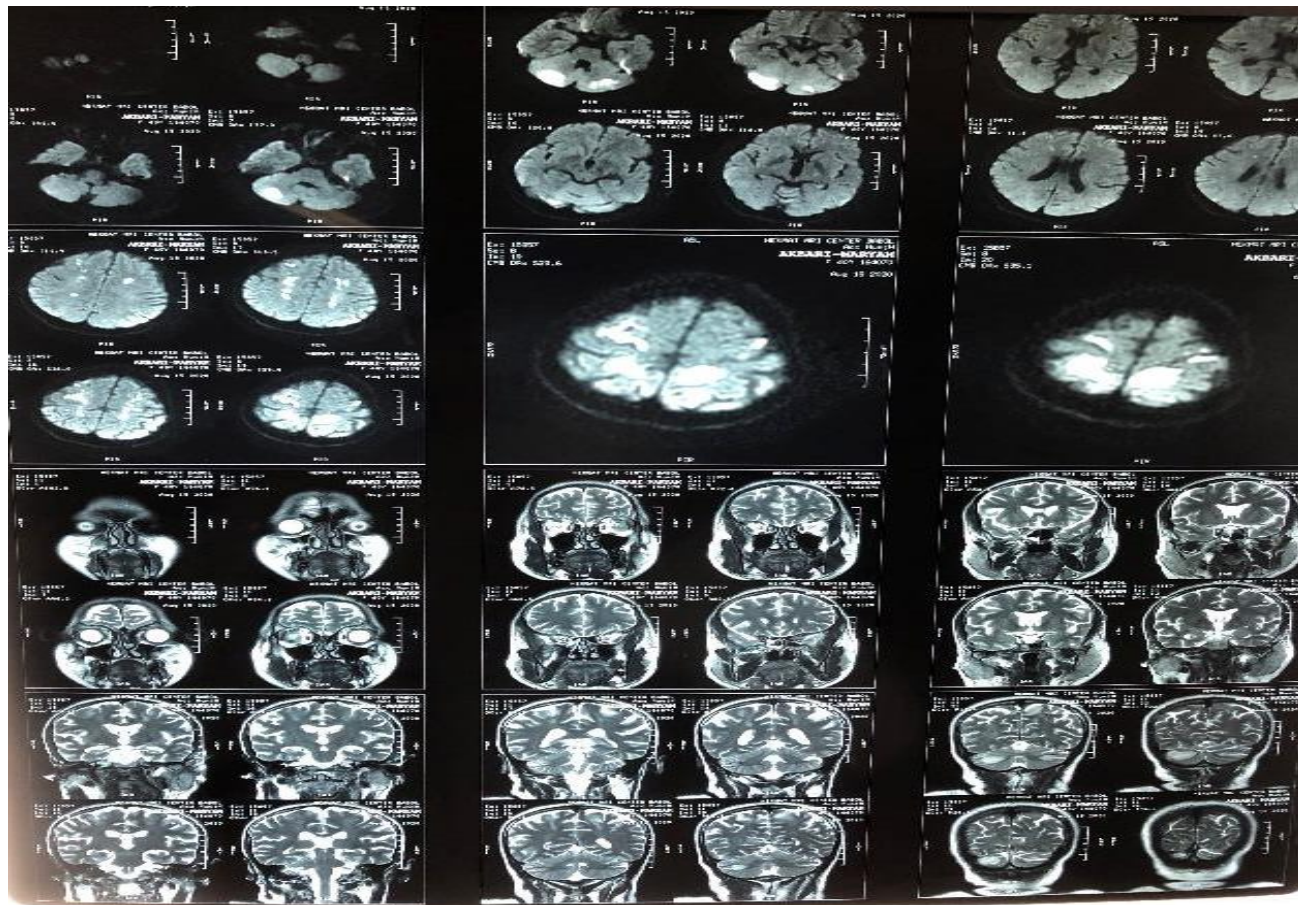


Fig3: Brain MRI(DWI): show bright signal areas(restrictions) in both cerebellar hemispheres and parieto-occipital(cortical and subcortical)compatible with acute ischemic insult.

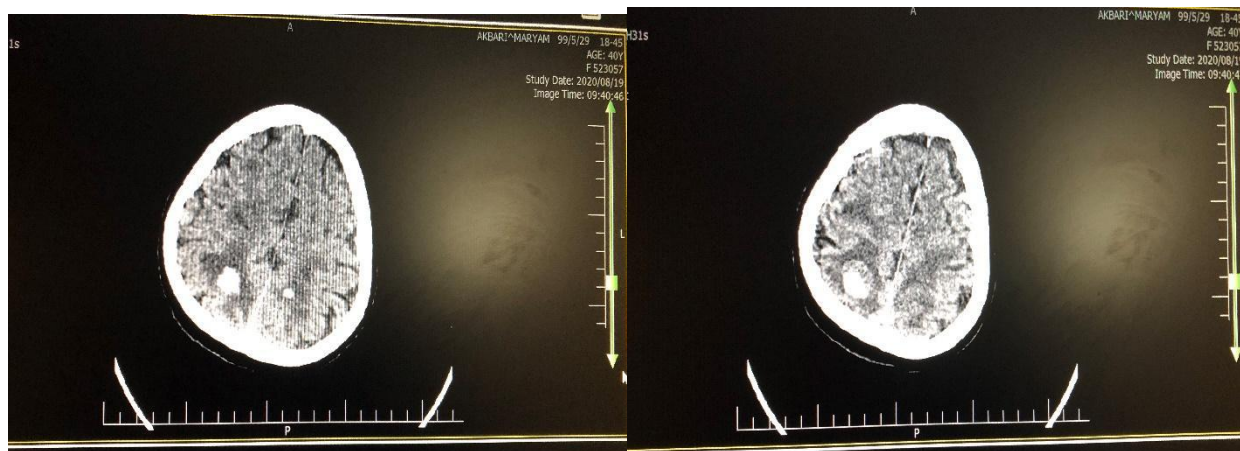


Fig4: Spiral Brain ct scan without contrast, hypodensity in the right parietal lobe and hyperdense centers inside it, this evidence can be suggestive for Ischemic infarction and Hemorrhagic transformation

Table-1

Serology	Result	Reference Range
B2 Microglobulin(Serum)	0.9	0.9-2
Anti Cardiolipin IgG	0.4	Negative:<12 Equivocal:12-18 Positive:>18
Anti Cardiolipin IgM	1.6	Negative:<12 Equivocal:12-18 Positive:>18
C3	100	90-180
C4	16	10-40
CH50	112	70-150
Sm	0.3	Negative:<0.8 Equivocal:0.8-1.2 Positive:>1.2
SS-B	0.3	Negative:<0.8 Equivocal:0.8-1.2 Positive:>1.2
Scl-70	0.3	Negative:<0.8 Equivocal:0.8-1.2 Positive:>1.2
CENP B	2.75	Negative:<0.8 Equivocal:0.8-1.2 Positive:>1.2
Jo-1	0.29	Negative:<0.8 Equivocal:0.8-1.2 Positive:>1.2
U1-RNP	0.26	Negative:<0.8

		Equivocal:0.8-1.2 Positive:>1.2
Sm/RNP	0.3	Negative:<0.8 Equivocal:0.8-1.2 Positive:>1.2
SSA52/60	0.33	Negative:<0.8 Equivocal:0.8-1.2 Positive:>1.2
ANA(ELISA)	183.8	Negative:<12 Equivocal:12-18 Positive:>18
Anti ds DNA(ELISA)	2.6	Negative:<25 Equivocal:25-40 Positive:>40
Procalcitonin	0.07	<0.1
D-Dimer	453	Up to 1000
Pro-BNP	183	Up to 125
IL-6	14.1	Up to 12
Anti-CCP(ELISA)	15	Negative:<25 Positive:>25
Anti Phospholipid IgG(ELISA)	0.8	Negative:<12 Equivocal:12-18 Positive:>18
Lupus Anticoagulant	Negative	Negative
Anti Phospholipid IgM(ELISA)	5.6	Negative:<12 Equivocal:12-18 Positive:>18
Serum Homocystein	12.2	5-20
PLT	184000	150000-450000
AST	79	<31
ALT	103	<31
LDH	734	<480
ALP	295	64-306
CRP	18	<10

ESR	15	<20
Triglyceride	610	<200
Cholesterol	240	<200
HDL	47	>35
LDL	101	<130

Consultation of neurosurgery and vascular surgery were requested for the patient. According to the patient's vascular surgery consultation, no special action was required. After performing the neurosurgery consultation, the patient's anticoagulant (enoxaparin) was held for 5 days, and then it was changed into subcutaneous heparin. On the second Brain CT, the patient's hemorrhage decreased. The patient is currently in good general condition and is recovering. After one week, the patient's heparin was discontinued, and she has discharged with the prescription of Atorvastatin 40mg, Plavix 75mg, and ASA 80mg Daily.

## Discussion

Acute stroke can be seen as a medical emergency even in the coronavirus pandemic. Most of the patients with coronavirus infection show symptoms, including respiratory symptoms. However, other patients show atypical gastrointestinal, cardiovascular, and neurological manifestations (7).

The coronavirus pandemic has involved all parts of the world that have stroke treatment centers, not only stroke patients are more susceptible to covid19 infections, but this pandemic is the most important indication of how we treat stroke care, following the safety of patients and health care personnel.

The ability of Coronavirus-associated coagulopathy is similar to sepsis-induced coagulopathy and prepares the ground for a stroke. The SARS-CoV 2 virus binds to the angiotensin-converting enzyme (ACE2) present on brain endothelial and smooth muscle cells (9).

Coronavirus infection can lead to changes in the coagulation and laboratory findings, including thrombocytopenia, increased D-dimer, increased prothrombin time (PT) and diffuse intravascular coagulation (DIC), and eventually the development of thrombosis (12).

There are several factors that can lead to acute stroke; however, the most important are arterial and cardiac embolism, arterial wall disease, and variants of these conditions. Additionally, hematologic disorders include lymphopenia and leukopenia, are related to ischemic stroke and lead to a poor prognosis in stroke (13).

Preliminary reports from China show that neurological symptoms are seen in approximately 36% of patients with covid-19 hospitalization. The bad consequences of this infection are related to vascular risk factors such as hypertension, coronary artery disease, and diabetes mellitus (14).

Several reports have raised concerns about the virus's aggressive tendency to the nervous system. Brain involvement in patients with meningitis, encephalitis, and finally ischemic stroke is due to thrombophilia (15).

The study by Li Y et al. Showed that the incidence of stroke in corona disease is approximately 5% at an average age of 71.6 years. The median time to stroke after corona diagnosis is 12 days (10).

The preliminary report of coronavirus outbreak by Zhou et al. confirms previous reports that say SARS-COV2 virus uses the same receptors to enter the cell as the SARS-COV virus, where ACE 2 is restricted to the membrane, which is expressed in neurons and endothelial cells and the smooth muscles of the cerebral arteries. The aforementioned fact allows the coronavirus to cross the blood-brain barrier and affect the central nervous system (16).

Patients with coronavirus infection have a higher risk of progressive stroke. In particular, it can be associated with multi-organ failure, the cause of which remains unclear. Also, acute stroke risk in patients with other respiratory tract infections has been reported (11).

A study by S Zayet et al. Showed that thrombotic stroke occurred during progressive anticoagulation for atrial fibrillation. Given the increasing realization that COVID-19 might be associated with hypercoagulability, the concurrent presence of anticoagulation with direct oral anticoagulants should not be reassuring as preventive. For this reason, the link between stroke and Covid-19 disease needs more attention (17).

A study by Gonzalez-Pinto et al. showed a strong association between SARS-COV2 and the progression of systemic thromboembolism due to increased coagulation status unrelated to the patient's age(18). Therefore, recognizing the manifestations of corona infection is crucial for rapid diagnosis and treatment. In this rapidly emerging pandemic, several cases of stroke have been reported in patients infected with SARS-CoV-2. However, a unique feature in the patient we report is multiple concurrent stroke.

## **Conclusion**

Corona disease is currently the most important infectious disease globally, which, despite the prevalence of pulmonary involvement, tends to involve other body organs, especially the brain. Therefore, due to the prevalence of this disease, more familiarity with physicians with rarer manifestations of the disease will help a lot in diagnosing and treating the disease and preventing the neurological complications of this disease, especially stroke.

## **Acknowledgements**

The authors would like to express their gratitude to the Clinical Research Development Unit of Rouhani Hospital in Babol.

## **Conflict of interest**

The authors declare no conflicts of interest.

## References

1. J. Matías-Guiu\*, U. Gomez-Pinedo, P. Montero-Escribano, P. Gomez-Iglesias, J. Porta-Etessam, J.A. Matias-Guiu, Should we expect neurological symptoms in the SARS-CoV-2 epidemic? *Neurología*, Volume 35, Issue 3, April 2020, Pages 170-175
2. Joy D. Iroegbu & Chibuzor W. Ifenatuoha & Omamuyovwi M. Ijomone, Potential neurological impact of coronaviruses: implications for the novel SARS-CoV-2, *Neurological Sciences* (2020) 41:1329–1337
3. Rodríguez-Pardo J, Fuentes B, Alonso de Lecinana M & et al, Acute stroke care during the COVID-19 pandemic. Ictus Madrid Program recommendations, *Neurología*, Volume 35, Issue 4, May 2020, Pages 258-263
4. Ali Z, Ullah W, Saeed R, Ashfaq A, Lashari B, Acute COVID-19 induced fulminant systemic vascular thrombosis: A novel entity, *IJC Heart & Vasculature* Volume 30, October 2020, 100620
5. Rajan A.G. Patel\* Christopher J. White John Ochsner Heart & Vascular Institute, Ochsner Medical Center, 1514 Jefferson Hwy., New Orleans, LA 70121, Stroke Treatment and Prevention, *Progress in Cardiovascular Diseases* Volume 59, Issue 6, May–June 2017, Pages 525-526
6. Strambo D, Sirimarco G, Inacio N, Eskandari A and Patrick Michel, Skiing Associated Stroke: Causes, Treatment, and Outcome, *Journal of Stroke and Cerebrovascular Diseases*, Vol. 28, No. 2 (February), 2019: pp 288-294
7. Avulaa A, Nalleballeb K, Narulaa N, Sapozhnikovc S, Dandub V, Toomd S, Glasere A, Elsayegh D, COVID-19 presenting as stroke, *Brain, Behavior, and Immunity*, Volume 87, July 2020, Pages 115-119
8. S Markus H and Brainin M, COVID-19 and stroke—A global World Stroke Organization perspective, *International Journal of Stroke* 2020, Vol. 15(4) 361–364
9. Hess D & Eldahshan W & Rutkowski E, COVID-19-Related Stroke, *Translational Stroke Research* (2020) 11:322–325
10. Avulaa A, Nalleballeb K, Narulaa N, Sapozhnikovc S, Dandub V, Toomd S, Glasere A, Elsayegh D, COVID-19 presenting as stroke, *Brain, Behavior, and Immunity*, Volume 87, July 2020, Pages 115-119
11. I Qureshi A, Abd-Allah F, Al-Senani F & et al, Management of acute ischemic stroke in patients with COVID-19 infection: Report of an international panel, *International Journal of Stroke* 2020, Vol. 15(5) 540–554
12. Gonzalez-Pinto T, Luna-Rodriguez A, Moreno-Estebanez A, Emergency room neurology in times of COVID-19: malignant ischaemic stroke and SARS-CoV-2 infection, Neurology Department, University Hospital Cruces, Bilbao, Spain, 2020 European Academy of Neurology
13. Zayet S, Klopfenstein T, Kovács R, Stancescu S, Hagenkötter B, Acute Cerebral Stroke with Multiple Infarctions and COVID-19, France, 2020, *Emerging Infectious Diseases* • www.cdc.gov/eid • Vol. 26, No. 9, September 2020
14. Belani P, Schefflein J, Kihira S, Rigney B, Delman B.N, Mahmoudi K, Mocco J, Majidi S, Yeckley J, Aggarwal A, Lefton D, and Doshi A.H, COVID-19 Is an Independent Risk Factor for Acute Ischemic Stroke, *AJNR Am J Neuroradiol* 41:1361–64 Aug 2020 www.ajnr.org
15. Al Saiegh F, Ghosh R, Leibold A & et al, Status of SARS-CoV-2 in cerebrospinal fluid of patients with COVID-19 and stroke, *J Neurol Neurosurg Psychiatry* 2020;91:846–848. doi:10.1136/jnnp-2020-323522
16. Al Saiegh F, et al, Status of SARS-CoV-2 in cerebrospinal fluid of patients with COVID-19 and stroke, *J Neurol Neurosurg Psychiatry* 2020;91:846–848. doi:10.1136/jnnp-2020-323522
17. Zayet S, et al, Acute Cerebral Stroke with Multiple Infarctions and COVID-19, France, 2020, *Emerging Infectious Diseases* • www.cdc.gov/eid • Vol. 26, No. 9, September 2020
18. T Gonzalez-Pinto, et al, Emergency room neurology in times of COVID-19: malignant ischaemic stroke and SARS-CoV-2 infection, 2020 European Academy of Neurology